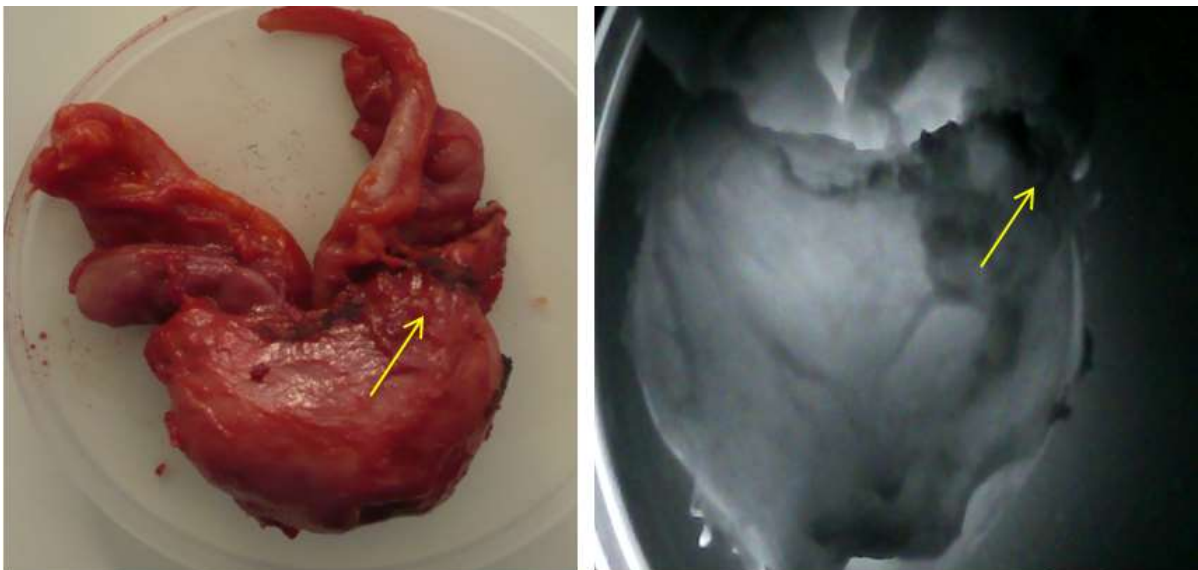


SUPPLEMENTARY MATERIALS

## Infrared Visualization of the Prostate Cancer

Sopio Abazadze<sup>1</sup>, Alexandre Khuskivadze<sup>1</sup>, Besarion Partsvania<sup>2</sup>, Tamaz Sulamberidze<sup>2</sup>,  
Davit Kochiashvili<sup>1</sup>, Omar Khardzeishvili<sup>3</sup>

**FIGURE S1.** White light (left) vs infrared light (right) images of the prostate cancer. The arrow is showing malignancy



**FIGURE S2.** White light (left) vs infrared light (right) images of the benign prostatic hyperplasia

