

Expression of IL-6 and CD68 Markers in Antemortem and Postmortem Fractures

Meri Gonashvili¹, Besarion Kilasonia¹, Ramaz Chikhladze², Rusudan Beriashvili¹

DOI: [10.52340/GBMN.2024.01.01.87](https://doi.org/10.52340/GBMN.2024.01.01.87)

ABSTRACT

Background: Estimation of the time of fracture and knowledge of differentiating characteristics between antemortem and postmortem fractures are important issues in forensic medical and anthropological examinations. Evaluation of the biological reactions to the fracture would require knowledge of the cellular response to the injury in connection to the time of occurrence and the roles played by the inflammatory markers IL-6 and the macrophage marker CD68 during bone healing after fractures.

Objectives: This study evaluated the IL-6 and CD68 expression differences between antemortem, postmortem, and perimortem fractures. The main aim was to evaluate the potential for these markers in discriminating fracture types and, as possible, specific time points of inflammation and repair regarding different periods.

Methods: The study was experimental. 78 adult Wistar rats were divided into 13 groups corresponding to the induction of fracture (antemortem, postmortem, or perimortem) and collection of samples. The bone tissues were subjected to immunohistochemical analysis for IL-6 and CD68 expression. The expression of the two markers was statistically analyzed using one-way ANOVA followed by posthoc tests to compare between groups.

Results: IL-6 expression was highest in antemortem fractures, particularly 24-hour fractures, and lowest in postmortem fractures. CD68 expression demonstrated a similar trend, with progressive increases in antemortem fractures and only minimal expression in postmortem fractures. While levels of both IL-6 and CD68 were still measurable in antemortem fractures with postmortem overlay, these were lower compared to antemortem fractures without postmortem overlay. These results imply that IL-6 and CD68 may be used to determine bone fracture vitality.

Conclusions: IL-6 and CD68 antibodies can be immunohistochemical markers to differentiate antemortem, postmortem, and perimortem fractures. Forensic doctors can use these markers to indicate the time of fracture in antemortem and postmortem injuries. Further research is needed to validate these findings in medico-legal case scenarios, particularly involving human tissues.

Keywords: Antemortem Fractures; CD68; Fracture Timing; IL-6; Perimortem Fractures; Postmortem Fractures.

BACKGROUND

Among the characteristics that must be assessed by forensic medical and anthropological examinations of the skeleton, differentiation between antemortem and postmortem fractures and dating antemortem fractures are fundamental. This issue is of great scientific interest and investigational importance for determining the role of physical violence in death.¹⁻³ This is of particular importance in cases of fractures to the ribs due to the resuscitative effort and, in addition, if investigations for child physical abuse are being undertaken. Investigative concerns regarding rib fractures include whether they occurred during resuscitative attempts or are antemortem injuries due to physical abuse.⁴⁻⁷

Immediately after a fracture, bleeding and hematoma formation begin. The formation of a hematoma is an important early event in fracture healing. The role of the hematoma is to provide a temporary scaffold for cells that take part in healing, mainly inflammatory small vessels, mesenchymal stem cells (MSCs), and osteoblasts, to deposit after the injury.⁸ The hematoma is also osteogenic, as removing it from the fracture will interfere with the reparation process.⁹

IL-6 is a major cytokine in the initial inflammatory response following fracture and has been found to have a complex and crucial role in the cascade of events leading to fracture healing.

Tohma (2017) presented that the IL-6/Reg pathway was critical to periosteum osteogenic response during fracture healing.¹⁰ Moreover, Johnson et al. (2020) emphasized the necessity of IL-6 regulation during wound healing, noting that dysregulation may result in fibrosis or impaired healing.¹¹ Wallace et al. (2011) supported this by demonstrating that the absence of IL-6 in mice exhibits reduced osteoclastogenesis and diminished bone callus density in the early stages after fracture.¹²

Hoff et al. (2017) performed a comprehensive time-dependent analysis of the composition of fracture hematoma. In the acute fracture (<72 hours old) group, hematoma immune cell subpopulations, cytokine concentrations, and chemokine content were observed in 42 human fractures, showing that early (day 0-1) human fracture hematomas are characterized by granulocyte maturation, indicating monocyte/macrophage migration and bone marrow progenitor cells differentiation. At around 24 hours, infiltrating T-helper and cytotoxic T lymphocytes proliferate or come from distant sites to the fracture site, and pro-inflammatory cytokines such as IL-6, IL-8, INF γ , TNF α , also anti-inflammatory cytokines like IL-1 receptor antagonist - IL-10 ultimately peak.¹³ The ability to detect macrophage expression using immunohistochemistry is extremely important, given the



critical importance of macrophages in fracture healing. M1 macrophages are closely associated with IL-6 expression in fracture healing, which are mainly active at initial phases, whereas M2 macrophages have a more significant role in the phase of mineralized callus formation.⁸ Hoff (2013) emphasized the ability of immune cells, including macrophages, to adapt to hypoxic conditions within the fracture hematoma.¹⁴ CD68 is a marker for macrophages in general, and the activity of macrophages indicates bone status at later time points. These antemortem fractures have a higher expression of CD68 due to the predominance of macrophages at their earliest stages. As there is no macrophage activity in the postmortem tissues, the lower level of CD68 expression makes it an important tool to differentiate between antemortem and postmortem fractures. Together, these studies highlight the role of cytokines such as IL-6 and macrophages in mediating the onset of early inflammation and modulating later events during fracture healing.¹⁵

METHODS

Experimental design

This experimental study was conducted in agreement with the Biomedical Research Ethics Committee of Tbilisi State Medical University. Adult Wistar rats (N = 78) were used in which both males and females were randomly selected.

This model uses Wistar rats, a commonly evaluated species in fracture models. These animals allow researchers to follow the different stages of fracture healing, from an inflammatory state to bone remodeling. These animals justify the relevance of translational explorations to bone healing and consolidation processes due to their physiological and genetic similarities with humans. Compared to larger mammals, this is also because their use is cost-effective and viable.¹⁶

The experiment was conducted at the Vivarium of the Alexander Natishvili Institute of Morphology, Tbilisi State University, by The Council Directive 2010/63/EU on protecting animals used for scientific purposes. The animals were kept in a quarantine facility for 2 weeks and allowed to acclimatize before the experiments under standard conditions (temperature: 25±3°C; light/dark cycle: 12 hours) with free access to water and normal rodent chow.¹⁷

Experimental groups and fracture induction

The rats were divided into 13 experimental groups, depending on the time of fracture induction and sample harvesting. The animal number for each group was six due to the guidelines of ethical subjects of good laboratory practice and fewer animals used, keeping in view the scientific validity.¹⁸

An intraperitoneal injection delivered general anesthesia of 70 mg/kg ketamine and 5 mg/kg xylazine to induce fractures. The percent reduction in the mean dosage of ketamine was 8.59 %, and that in xylazine was 9.90 %. A standardized closed femur fracture was produced, as described by Handool et al. (2018). After the fracture, rats were housed separately, and their fractured limbs were free-banded to move freely.¹⁹

Animal groups

Animals in groups N1, N2, and N3 underwent antemortem fractures, and euthanasia was performed at 1, 6, and 24 hours after fracturing in the respective group, and the samples were taken immediately. In groups N4, N5, and N6, post-mortem fractures were induced 1 hour, 6 hours, and 12 hours after death; samples were taken immediately. Groups N7, N8, and N9 had fractures induced immediately post-mortem, with samples collected 1 hour, 6 hours, and 12 hours after fracture. Group N10 underwent fracture immediately after death, and samples were collected simultaneously. Groups N11, N12, and N13 received antemortem fractures, and samples were collected 1 hour, 6 hours, and 12 hours post-euthanasia.

Animals were euthanized by ether inhalation, and bone samples from each animal were harvested and kept in 10% buffered formalin for a minimum of 48 hours.^{20,21}

Tissue decalcification and processing

Bone samples were decalcified using Buffer Versanate Decalcifying Solution (American Master Tech) containing EDTA. The decalcification process was observed every 3 to 4 days between each cycle to preserve the tissue efficiently. This was followed by 3–4 weeks of decalcification before the samples were washed with running water for 10 minutes.²²

Bone samples removed from the decalcification solution were placed into metal cassettes, autofixed, and processed in a Sakura Histo-Tech® VP1™ tissue processor using an automated "Overnight" program that lasted about 64 hours. After dehydration in a graded ethanol series, the samples were cleared in xylene and embedded in paraffin.

Tissues subjected to processing were paraffin-embedded in Leica HistoCore Arcadia H (Leica Biosystems, Wetzlar, Germany) at 65°C and rapidly cooled down to prevent crystallization and facilitate section cutting. The thickness of sections was maintained at 5 microns using a rotary microtome (Leica RM2235) to trim the paraffin block.

Immunohistochemical analysis was performed to evaluate bone healing markers. The following primary antibodies were used:

- IL-6 (monoclonal antibody IL-6, AA 21–211; Antibodies-online, ABIN7427095) was used.^{8,23} for evaluation of early inflammatory response in fracture regions;
- CD68 (monoclonal antibody CD68, Bond RTU Primary, 110 KDA; Leica CD68-L-CE) to stain pro-inflammatory M1 macrophages in fracture hematomas.²⁴

The appendix for IL-6 and tonsil for CD68 were used as positive control tissues to assess the validity of the staining protocols.

Digital and manual cell counting

HALO Image Analysis Software for Automated Counting of Immunohistochemically stained cells Image Analysis of digital microscopic images at 10X, 20X, and 40 X magnification using HALO software (HALO Image Analysis Software v3.6.4134.396,

Albuquerque, NM, USA) This software had been trained to identify positively stained cells in immunohistochemically stained samples.²⁵

Immunohistochemically stained cells were also manually counted using QuPath software. A square ocular grid overlay examined digital microscopy images, and cells were manually counted.²⁶

Statistical Analysis

The levels of IL-6 and CD68 were calculated in each group through descriptive statistics, expressing the results as mean, standard deviation, minimum, and maximum. This gave an estimate of cell distribution and central tendencies in immunopositive cells. The data distribution was checked for symmetry and normality using Skewness and Kurtosis tests. Values less than zero suggest the data was parametric and suitable for testing.

Using one-way ANOVA, we tested whether statistical differences of IL-6 and CD68 expressions were observed among the antemortem fracture group, postmortem fracture group, and perimortem fracture group in the present study. A p-value less than 0.05 was considered statistically significant. Post-hoc analysis used Tukey's Honest Significant Difference (HSD) test to compare pairs of groups and find where expressions were significantly different with multiple comparisons adjustment. The same test used a Chi-square test on these variables (e.g., the percentage of immunopositive cells). The Pearson Chi-Square statistic was used to analyze the relationship between fracture patterns and IL-6/CD68 expression, with p-values less than 0.05 indicating significant associations.

RESULTS AND DISCUSSION

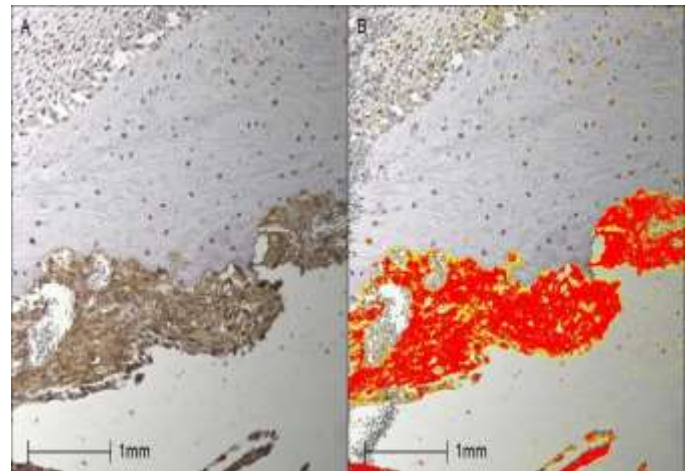
IL-6 Expression

IL-6, an important inflammatory cytokine, was differentially expressed between antemortem fracture, postmortem, and perimortem fractures. Among the antemortem fracture groups (Groups 1-3), injury duration was associated with a significant increase in IL-6 expression (Fig.1). IL-6 expression was highest in group 3 (24-hour antemortem fractures); the mean score was 16.42 ± 0.79 , 2.13 times higher than in group 1 (1-hour antemortem fractures - 7.71 ± 0.37). Expression levels were between the two other study groups, with a mean score of 10.70 ± 0.50 in group 2 (6-hour ante-mortem fractures). These data also indicate that IL-6 is early induced in bone injury, suggesting its important role in the initial stages of the healing process. The time-dependent increase in IL-6 reflects the cytokine's involvement in recruiting inflammatory cells and promoting tissue repair during early fracture healing.

The postmortem fractures (Groups 4-6) had significantly lower levels of IL-6, consistent with the termination of inflammatory responses occurring with death (Fig.2). Regarding the number of IL-6 positive cells, Group 4 (1-hour postmortem group) had 2.14 ± 0.10 . while Groups 5 and 6 had further reduced levels of 1.55 ± 0.07 and 1.53 ± 0.06 ,


respectively. The minimal differences between groups of postmortem fractures reflect how quickly inflammation ceases after death and possibly can be used to distinguish antemortem from postmortem fractures in future forensic cases.

FIGURE 1. Group 3 - 24-hour antemortem fracture, sample collected immediately after animal euthanasia



Explanations: A, periosteum and bone show strong IL-6 expression; B, the same tissue was analyzed using HALO Image Analysis Software, with intensity levels marked by colors: red indicates strong expression, orange indicates moderate expression, and yellow indicates weak expression.

FIGURE 2. Group 4 - fracture occurring 1 hour postmortem, sample collected immediately after fracture




Explanations: Bone marrow shows a negative IL-6 reaction.

Perimortem fracture groups (Groups 7-10) showed equally stable levels (Fig.3) and only slightly elevated staining for the IL-6 marker, ranging from as low as 2.12 ± 0.09 to a maximum of 2.31 ± 0.08 . These results indicate the near-complete absence of biological activity shortly after death.

The antemortem fracture groups overlaid the postmortem period (Groups 11-13). IL-6 expression was still detectable but to a lesser extent than in pure antemortem fractures. Group 13 (6-hour fractures under postmortem over-laying) had a significantly higher number of IL-6 positive cells, as compared

to Group 11 (8.84 ± 0.42) and Group 12 (12.62 ± 0.61). This suggests that IL-6 can be detected in fractures caused before death despite postmortem changes. This is of importance in forensic contexts since IL-6 could, therefore, be a suitable marker to distinguish between antemortem and postmortem fractures, as in antemortem fractures with postmortem overlay trauma sceneries.

FIGURE 3. Group 7 - Fracture Induced 1 Hour Postmortem, Sample Collected 6 Hours After Death



Explanations: Bone shows a negative IL-6 reaction

CD68 Expression

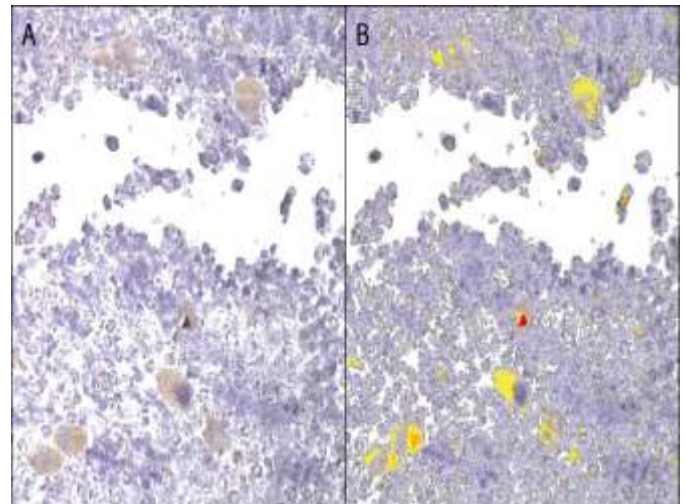
The activity of macrophage lineage cells, defined by CD68 immunostaining, tended to vary similarly among the fracture groups. The expression of CD 68 in antemortem fracture groups (groups 1-3) increased progressively with time (Fig.4). The mean expression level was 8.22 times for Group 3 (24-hour fractures), with a mean score of 6.82 ± 0.30 . Group 1 (0.83 ± 0.02) and Group 2 also demonstrated increased expression of CD68 (5.91 ± 0.29) and showed the role of macrophage migration, an essential process in bone healing. The increased CD68 expression over time is likely due to increasing numbers of macrophages involved in removing debris and tissue remodeling essential to the normal bone healing process.

CD68 expression was somewhat limited in postmortem fractures (Groups 4-6), with values varying from 0.67 ± 0.01 in Group 4 to 0.34 ± 0.01 in Group 6 (Fig.5). This result suggests that macrophage activity after death has not occurred, which is a viable consequence due to the termination of immune system action. There does not appear to be a significant inflammatory response, and the CD68 levels remained low and relatively stable throughout all postmortem groups.

In antemortem fractures with postmortem overlay (Groups 11-13), Group 13 demonstrated the most significant increase of CD68 expression (6.1 ± 0.29) versus Groups 11 (1.34 ± 0.02) and Group 12 (1.40 ± 0.11), respectively. This indicates macrophage activity can be detected even in antemortem fractures with postmortem overlay but at a low level compared to pure antemortem injuries. The present study

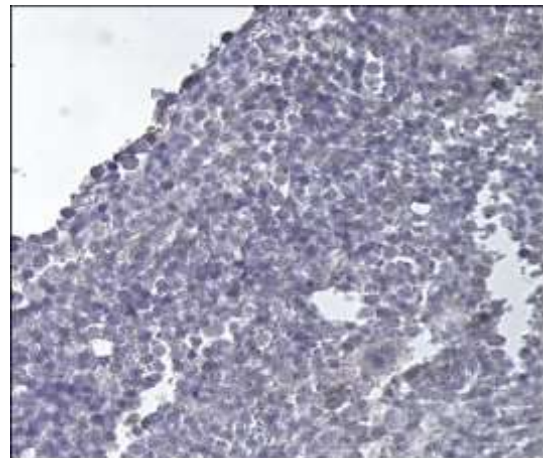
indicates that CD68 can serve as a marker for antemortem fractures even in the presence of post-mortem changes.

FIGURE 4. Group 2 - 6-Hour Antemortem Fracture, Sample Collected Immediately After Animal Euthanasia



Explanations: Bone marrow shows CD68 expression in macrophages. B) The same tissue was analyzed using HALO Image Analysis Software, with macrophage CD68 expression marked by colors: red indicates strong expression, orange indicates moderate expression, and yellow indicates weak expression.

FIGURE 5. Group 4 - 1 Hour Postmortem Fracture, Sample Collected Immediately After Fracture



Explanations: Bone marrow shows a negative CD68 expression.

Limitations and future directions

Although the study is based on animal models (Wistar rats), more is needed to simplify translation to human forensic practice. Human tissue samples for research purposes are often challenging to obtain due to ethical considerations and support the necessity of additional studies in human cadavers/donated bodies to help fill the gap between animal models and real-world forensic cases. This restriction further emphasizes the need to validate these markers in human forensic scenarios.

Moreover, the study only focused on long bones, not flat bones, which limits the scope of the findings. There might be differences in inflammatory or healing responses to flat bones. Nevertheless, a more systematic analysis using additional mesoscopic markers for the flat bones is required to fully evaluate the utility of these markers in different types of bone fractures encountered in forensic settings.

Furthermore, more precisely, there is an urgent call to investigate the perimortem period. This period is critical to forensic investigations, especially regarding the post-mortem interval and manner of death. A more comprehensive evaluation concerning IL-6, CD68, and other possible markers in the perimortem time of fracture will significantly reinforce the diagnosis of the distinction between antemortem and postmortem fractures in forensic medical practice.

CONCLUSIONS

The study's findings indicate that IL-6 and CD68 are helpful immunohistochemical markers to differentiate between antemortem, postmortem, and antemortem fractures with postmortem overlay. The highly elevated IL-6 from antemortem fractures indicates a strong immune response to bone injury. In contrast, the low-level expression associated with postmortem fractures may indicate cessation of cell biological activity. These differences are of critical forensic importance since they underlie a cell biological model by which the timing of fractures relative to death may be determined.

Besides, the immunohistochemical detection of IL-6 and CD68 in antemortem fractures with the overlay due to post-mortem changes indicates that these markers could be helpful in complex forensic cases where injuries may arise before and after death. These markers contribute to the timing of fractures and discriminate between sequential injuries by forensic pathologists.

However, CD68 has emerged as another useful marker, with positive staining for antemortem fractures in the presence of postmortem changes, although it is less prominently expressed compared to IL-6. The results provide new perspectives on how IL-6 and CD68 could be helpful for forensic casework when studying the inflammation process surrounding bone healing in life and death.

AUTHOR AFFILIATIONS

¹ Department of Forensic Medicine, Tbilisi State Medical University, Tbilisi, Georgia;

² Department of Pathological Anatomy, Tbilisi State Medical University, Tbilisi, Georgia.

ACKNOWLEDGEMENTS

This work was supported by the Shota Rustaveli National Science Foundation (SRNSF) [grant number PHDF-23-3290, project title: "Morphological Characteristics of Antemortem and Postmortem Long Bone Fractures."]

REFERENCES

- Cappella A, Amadasi A, Castoldi E, Mazzarelli D, Gaudio D, Cattaneo C. The difficult task of assessing perimortem and postmortem fractures on the skeleton: a blind text on 210 fractures of known origin. *J Forensic Sci.* 2014;59(6):1598-1601. doi:10.1111/1556-4029.12539.
- Cappella A, Cattaneo C. Exiting the limbo of perimortem trauma: A brief review of microscopic markers of hemorrhaging and early healing signs in bone. *Forensic Sci Int.* 2019;302:109856. doi:10.1016/j.forsciint.2019.06.014.
- Dettmeyer RB. Vitality, Injury Age, Determination of Skin Wound Age, and Fracture Age. In: *Forensic Histopathology.* Springer; 2011. doi:10.1007/978-3-642-20659-7_10.
- James R. Rib histology after unsuccessful cardiopulmonary resuscitation in infants suffering sudden death from natural causes; implications for injury mechanism and timing. *Histopathology.* 2020;77(6):868-877. doi:10.1111/his.14270.
- Klotzbach H, Dellling G, Richter E, Spherhake JP, Püschel K. Post-mortem diagnosis and age estimation of infants' fractures. *Int J Legal Med.* 2003;117(2):82-89. doi:10.1007/s00414-002-0338-3.
- Raynor E, Konala P, Freemont A. The detection of significant fractures in suspected infant abuse. *J Forensic Leg Med.* 2018;60:9-14. doi:10.1016/j.jflm.2018.09.002.
- Viero A, Obertová Z, Cappella A, et al. The problem of dating fractures: A retrospective observational study of radiologic features of fracture healing in adults. *Forensic Sci Int.* 2021;329:111058. doi:10.1016/j.forsciint.2021.111058.
- Hoff P, Gaber T, Strehl C, et al. Immunological characterization of the early human fracture hematoma. *Immunol Res.* 2016;64(5-6):1195-1206. doi:10.1007/s12026-016-8868-9.
- Grundnes O, Reikeras O. The importance of the hematoma for fracture healing in rats. *Acta Orthop Scand.* 1993;64(3):340-342. doi:10.3109/17453679308994597.
- Tohma Y, Dohi Y, Shobatake R, et al. Reg gene expression in periosteum after fracture and its in vitro induction triggered by IL-6. *Int J Mol Sci.* 2017;18(11):2257. doi:10.3390/ijms18112257.
- Johnson BZ, Stevenson AW, Prêlle CM, Fear MW, Wood FM. The role of IL-6 in skin fibrosis and cutaneous wound healing. *Biomedicines.* 2020;8(5):101. doi:10.3390/biomedicines8050101.
- Wallace A, Cooney TE, Englund R, Lubahn JD. Effects of interleukin-6 ablation on fracture healing in mice. *J Orthop Res.* 2011;29(9):1437-1442. doi:10.1002/jor.21367.
- Hoff P, Gaber T, Strehl C, et al. A pronounced inflammatory activity characterizes the early fracture healing phase in immunologically restricted patients. *Int J Mol Sci.* 2017;18(3):583. doi:10.3390/ijms18030583.
- Hoff P, Gaber T, Strehl C, et al. Immunological characterization of the early human fracture hematoma. *Immunol Res.* 2016;64(5-6):1195-1206. doi:10.1007/s12026-016-8868-9.
- Hoff P, Maschmeyer P, Gaber T, et al. Human immune cells' behavior and survival under bioenergetically restricted conditions in an in vitro fracture hematoma model. *Cell Mol Immunol.* 2013;10(2):151-158. doi:10.1038/cmi.2012.56.
- Gao H, Huang J, Wei Q, He C. Advances in Animal Models for Studying Bone Fracture Healing. *Bioengineering (Basel).* 2023;10(2):201. doi:10.3390/bioengineering10020201.
- Directive 2010/63/EU of the European Parliament and of the Council of 22 September 2010 on the protection of animals used for scientific purposes. *Off J Eur Union.* 2010;L276:33-79. Accessed October 8, 2024. <https://eur-lex.europa.eu/legal-content/EN/TXT/?uri=CELEX:32010L0063>.
- Smith AJ, Clutton RE, Lilley E, Hansen KE, Brattelid T. PREPARE: Guidelines for planning animal research and testing. *Lab Anim.* 2018;52(2):135-141. doi:10.1177/0023677217724823.
- Handool KO, Ibrahim SM, Kaka U, et al. Optimization of a closed rat tibial fracture model. *J Exp Orthop.* 2018;5(1):13. doi:10.1186/s40634-018-0128-6.
- Aguwa US, Eze CE, Obinwa BN, et al. Comparing the Effect of Methods of Rat Euthanasia on the Brain of Wistar Rats: Cervical Dislocation, Chloroform Inhalation, Diethyl Ether Inhalation and Formalin Inhalation. *J*

Adv Med Med Res. 2020;32(17):8-16.
doi:10.9734/jammr/2020/v32i1730636.

21. Proding PM, Bürklein D, Foehr P, et al. Improving results in rat fracture models: Enhancing the efficacy of biomechanical testing by a modification of the experimental setup. *BMC Musculoskelet Disord.* 2018;19(1):2155. doi:10.1186/s12891-018-2155-y.
22. Dey P. Decalcification of Bony and Hard Tissue for Histopathology Processing. In: *Basic and Advanced Laboratory Techniques in Histopathology and Cytology.* Springer; 2018:35-39. doi:10.1007/978-981-10-8252-8_4.
23. Prystaz K, Kaiser K, Kovtun A, et al. Distinct Effects of IL-6 Classic and Trans-Signaling in Bone Fracture Healing. *Am J Pathol.* 2018;188(2):474-490. doi:10.1016/j.ajpath.2017.10.011.
24. Frade BB, Dias RB, Gemini Piperni S, Bonfim DC. The role of macrophages in fracture healing: a narrative review of the recent updates and therapeutic perspectives. *Stem Cell Investig.* 2023;10:4. doi:10.21037/sci-2022-038.
25. HALO Image Analysis Software, Version X. Indica Labs; 2024. Accessed May 8, 2024. <https://www.indicalab.com/halo>.
26. Bankhead P, Loughrey MB, Fernández JA, et al. QuPath: Open source software for digital pathology image analysis. *Sci Rep.* 2017;7:16878. doi:10.1038/s41598-017-17204-5.