

Comparative Analysis of Pilonidal Abscess Drainage

Erekle Gratiashvili,^{1,2} Lali Akhmeteli,¹ Teimuraz Ivanishvili,¹ Salome Kobadze,¹
Nodar Giorgadze²

DOI: [10.52340/GBMN.2023.01.01.39](https://doi.org/10.52340/GBMN.2023.01.01.39)

ABSTRACT

Background: A chronic sinus or a fast recurrence occurs after simple drainage of an acute pilonidal abscess. It is reasonable to expect that the risk of recurrence will reduce if the acute abscess is removed with minimal excision of the primary orifices.

Objectives: Our study aimed to evaluate the effectiveness of pilonidal abscess drainage performed by minimal excision of the primary ducts.

Methods: From January 2019 through April 2022, 120 patients with pilonidal abscesses underwent outpatient proctology surgeries at the Todua Clinic (19 females, 101 males; age range, 18-57 years). Sixty underwent drainage through an incision made by minimal excision of the primary ducts (Group 1), and the other 60 underwent simple drainage by dissection of the skin closest to the abscess (Group 2). Complete wound healing, the time of healing, recurrence, and complication rates were defined as the primary comparisons and success criteria. The length of the procedure, the time spent in the hospital, the time missed from work, the severity of the intraoperative pain, and the postoperative cosmetic outcomes were secondary variables. After surgery, an average follow-up time was 28 months (12-42 months).

Results: In the simple drainage group, complete healing was achieved in 35 patients (58.3%), and in the excision group - in 58 patients (96.6%) - $\chi^2=25.07$, $p<0.001$. Wound healing was rapid in the simple drainage group - 3.1 ± 1.4 weeks, and 5.3 ± 1.8 weeks - in the excision group ($p<0.001$). There were no significant differences in terms of complication rates. In the simple drainage group, an abscess developed in 1 case (1.66%) within ten days after surgery; in the excision group, a wound infection developed in 2 cases (3.3%). In the simple drainage group, recurrence occurred in 15 cases (25.0%), and in the excision group - in 1 case (1.7%) - $OR=19.7$ (95%CI - 2.5-154.5, $p=0.005$). No significant difference was found in cosmetic results, length of hospital delay, and period off work.

Conclusions: Compared to simple drainage, pilonidal abscess drainage with excision of the primary ducts has a significantly better rate of complete cure and a lower recurrence rate. It is a safe outpatient operation that can be recommended as the first-line therapy for an acute pilonidal abscess.

Keywords: Abscess drainage; limited excision; pilonidal disease; simple incision.

INTRODUCTION

Acute sacrococcygeal pilonidal disease, with a 14-20% prevalence, is painful and sometimes life-threatening. The abscess is the first manifestation of pilonidal illness in more than 50% of cases.¹ The average worldwide incidence of the disease is 26 cases per 100,000. PD is most widespread in the Caucasus region and occurs three times more often in men than women.¹

Congenital and acquired etiopathogenesis are the two primary hypotheses for pilonidal disease. However, the pathogenesis of the disease still needs to be clarified.¹

The first clinical manifestation of pilonidal disease can be related to the activity of sex hormones. Since they act on the secretion of sebaceous glands, the disease mainly develops at the age of 16-40 with pain and swelling in the natal cleft and a long-term decrease in daily activity.¹⁻⁴

Risk factors for its development are family history, deep intergluteal groove, obesity, young age, hirsutism, excessive sweating, local long-term pressure, friction, and insufficient hygiene.²

The treatment choice for any subcutaneous abscess, as well as pilonidal abscess, is surgical. The aim is to eliminate

the purulent process, often achieved by simple abscess drainage. However, a recurrence or chronic sinus develops if a pilonidal sinus abscess (PSA) is treated with a simple incision.⁵ Therefore, extended excision of the abscess by leaving the wound open is frequently used by surgeons in various countries, including Georgia, to reduce the frequency of a relapse. However, the healing process is quite long and often takes several months.⁶ In the case of excision of an acute abscess and wound repair, postoperative complications are common, and relapse often reaches 20%. There is evidence of positive results of small-scale drainage and curettage of the pilonidal abscess, significantly reduced recurrence rates, and rapid wound healing.^{7,8}

Our study aimed to evaluate the effectiveness of pilonidal abscess drainage performed by minimal excision of the primary ducts.

METHODS

From January 2019 to April 2022, 120 patients (19 females, 101 males; age range, 18-57 years) with acute pilonidal disease/pilonidal abscess were selected for the cross-



sectional study after obtaining informed consent and treated surgically at the Department of Coloproctology of Todua Clinic (Tbilisi, Georgia). Patients were distributed among two study groups. Group 1 consisted of 60 patients who underwent drainage through an incision made by minimal excision of the primary ducts (Tab.1). Group 2 consisted of another 60 patients who underwent simple drainage by dissection of the skin closest to the abscess (Tab.1).

TABLE 1. The characterization of study groups

Parameters	Group 1 N=60	Group 2 N=60	Chi ² , p-value
Male, n(%)	51 (85.0%)	50 (83.3%)	0.06, 0.803
Female, n(%)	9 (15.0%)	10 (16.7%)	0.06, 0.803
Min-max age, years	18-57	18-50	
Primary PSA	51 (85.0%)	49 (81.7%)	0.24, 0.626
Recurrent PSA	9 (15.0%)	11 (18.3%)	0.24, 0.626

Abbreviations: PSA, pilonidal sinus abscess

Sixty patients of the first group underwent drainage of the abscess from the incision made with minimal excision of the primary ducts (Fig.1). Patients were placed in the prone position. After the lateral exposition of the buttocks with adhesive pads (in case of necessity), the operative field was treated with povidone-iodine solution, and local infiltration anesthesia was performed around the primary orifices with 2% lidocaine + 0.005% epinephrine solution. Using an ultra-high radio frequency device (Dr. Oppel ST-501, Electrodes - J03; E04), the primary ducts were excised as holes approximately 5-8 mm in diameter and 0.7-1.2 cm in depth (Fig.1).

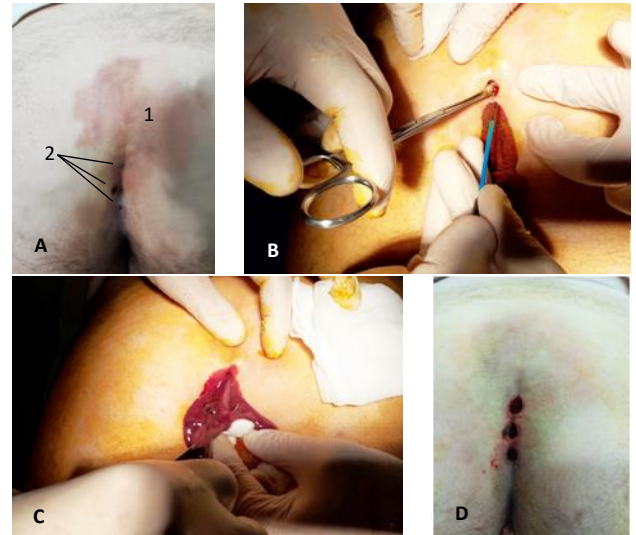
If the excised canals were insufficient for drainage, we expanded the canals and identified and drained the abscess cavity with a "Mosquito" type clamp. Abscess curettage and washing with antiseptic solutions were also performed (Fig.1).

In the case of a large abscess, for complete drainage, we performed an additional simple incision on the area closest to the skin of the abscess and made a curettage. We ended the operation by putting an antiseptic pad with povidone iodine ointment in the wound.

Sixty patients in the second group underwent simple drainage (Fig.2). Patients were prone. The operative field was treated with the povidone-iodine solution. Local infiltrative anesthesia was performed laterally to the midline, at the most superficial area of the abscess, with 2% lidocaine + 0.005% epinephrine solution. Abscess drainage was performed by applying a simple incision on the most superficial area of the abscess through an ultra-high radio frequency device (Dr. Oppel ST-501, Electrodes - J03; E04). If the abscess area was large, we made an ellipsoid excision of the wound edges. Then, the abscess was washed with hydrogen peroxide and betadine solutions. We ended the

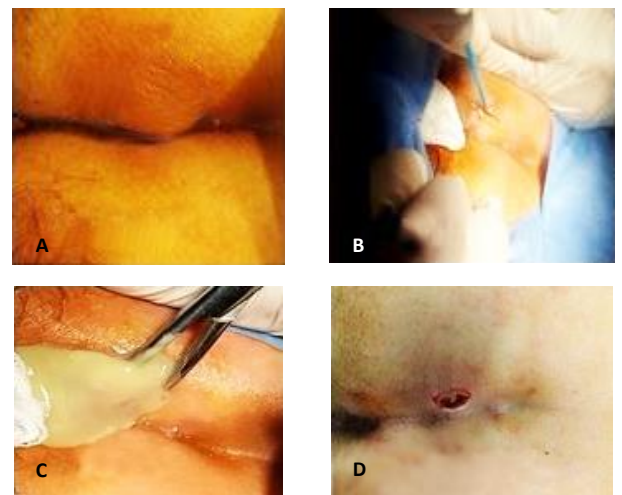
operation by putting an antiseptic pad with povidone iodine ointment in the wound (Fig.2).

FIGURE 1. The surgical treatment of pilonidal sinus abscess via drainage through an incision made by minimal excision of the primary ducts



Explanations: A. Pilonidal sinus abscess before the procedure: 1. Abscess; 2. Primary ducts; B. The excision of primary ducts; C. The curettage of abscess; D. Pilonidal sinus abscess after the procedure.

FIGURE 2. The surgical treatment of pilonidal sinus abscess via simple drainage by dissection of the skin closest to the abscess



Explanations: A. Pilonidal sinus abscess before the procedure; B. The skin dissection; C. The draining of abscess; D. Pilonidal sinus abscess after draining.

RESULTS

Complete healing was achieved in 35 patients (58.3%) of the simple drainage group and 58 patients (96.6%) of the excision group (Tab.2). The difference was statistically significant (Chi²=25.07, p<0.001). Wound healing was significantly faster in the simple drainage group compared to the excision group (p<0.001). All recurrences were detected during the first year after the procedure.

Recurrence occurred in 15 patients of the simple drainage group and one (1.7%) of the excision group. The difference was statistically significant ($\chi^2=14.02$, $p<0.001$). The odds ratio (OR) was 19.7, 95% CI (2.5, 54.5), $p=0.005$.

TABLE 2. The distribution of the healing parameters among the different groups of patients

Parameters	Group 1	Group 2	Chi ²	t-test	p-value
Complete healing, n (%)	58 (96.6%)	35 (58.3%)	25.07	-	<0.001
Healing time, weeks, M±SD	5.3±1.8	3.1±1.4	-	7.47	<0.001
Recurrence rate, n (%)	1 (1.7%)	15 (25.0%)	14.02	-	<0.001
Procedure duration, min., M±SD	16.7±6.1	10.7±4.8	-	5.39	<0.001
Intraoperative pain					
No, n (%)	37 (61.7%)	40 (66.7%)	5.22	-	0.074
Mild, n (%)	18 (30.0%)	20 (33.3%)			
Moderate, n (%)	5 (8.3%)	0 (0.0%)			
Severe, n (%)	0 (0.0%)	0 (0.0%)			
Complication rate, n (%)	2 (3.3%)	1 (1.7%)	0.34	-	0.560
Hospital delay, hours, M±SD	1.4±0.9	1.2±0.8	-	1.29	0.201
Return to the usual daily activity, days, M±SD	2.1±1.0	1.9±1.1	-	1.04	0.300

Abbreviations: M±SD, Mean ± Standard Deviation; n, number.

The duration of the operation in the simple drainage group was, on average, 10.7±4.8 min, while in the excision group, it was relatively longer - 16.7±6.1 min ($p<0.001$).

The difference in intraoperative pain was not statistically significant, but it was more intense in the excision group. In the simple drainage group, only mild intraoperatively pain was noted in 20 patients (33.33%), while in the excision group, mild pain was observed in 18 patients (30%) and moderate pain in 5 patients (8.33%). There was no statistically significant difference.

In most cases, mild pain was reported in the postoperative period, which did not require painkillers. Only two patients in the simple drainage group reported mild pain by week three.

In the postoperative period, in most cases, mild pain was observed, which did not require painkillers. In the simple drainage group, only two patients had mild pain by week 3. The same result was observed in the excision group by week 5.

There were no significant differences in complication rates, length of the hospital delay, and return to the usual daily activity. In the simple drainage group, an abscess developed in 1 case (1.76%) within ten days after surgery; in the excision group, a wound infection developed in 2 cases (3.3%). From a cosmetic point of view, the result was satisfactory for all patients. All patients returned to their usual lifestyle within one week.

In cases of abscessed recurrence, we performed drainage with minimal excision of the primary orifices. Complete healing after repeated procedures was achieved in 15 out of 16 patients (93.3%). In 1 patient, a simple form of the chronic sinus was developed.

Unhealed forms were treated with laser obliteration (FiLaC™ et al., diode laser device, radial emitting fiber, wavelength 1470nm and power 12W) or wide excision, leaving the wound open.

DISCUSSION

Even though pilonidal disease has been known for more than 200 years, no generally accepted treatment standard for either the acute or chronic form has been developed. Traditional surgical interventions are often accompanied by prolonged and painful rehabilitation. For the treatment of chronic pilonidal disease, the most common treatment is a wide excision of the pilonidal cyst, leaving the wound open, after which the healing period is significantly extended.⁹ Because of this, many methods of wound recovery after excision have been developed.¹⁰ According to the new guidelines, direct midline wound repair is not recommended due to the high risk of complications and recurrence.¹¹ Fewer complications characterize asymmetric restoration by the Karydakos and Bascom technique.^{12,13} Also, good results were obtained by Limberg and rotational flaps. However, despite its radicality and the difficulty of execution, most of these treatment methods are characterized by a high recurrence rate and complications, so wound repair with plastic flaps is recommended in complex, repeated chronic diseases.¹⁴ Traditional surgical operations have been actively replaced by less invasive methods for treating pilonidal disease. Compared to traditional methods, minimally invasive procedures are characterized by much shorter treatment periods and not a high recurrence rate.¹⁵ Among the minimally invasive methods for treating chronic pilonidal diseases, such as the treatment with phenol injections,¹⁶ the usage of fibrin glue,¹⁷ the obliteration of the sinus and its ducts with a diode laser device,¹⁸ the laser hair removal,¹⁹ for the treatment of pilonidal abscess using only the endoscopic method, which was first used for the treatment of chronic pilonidal disease.^{20,21}

Most often, simple drainage is used to treat pilonidal abscess, recommended laterally, not in the midline, because the healing process is faster. The procedure is performed on an outpatient basis under local anesthesia. An easy-to-perform and easily tolerated operation, patients soon return to their normal lifestyle, but unfortunately, chronic sinus formation or abscess recurrence often follows. Therefore, repeated operations are often necessary.^{5,22} Extensive excision of the abscess, leaving the wound open, or marsupialization is often resorted to achieve complete healing. In this case, the recurrence of the disease decreases, but the rehabilitation period is significantly prolonged.^{6,23} In order to reduce the rehabilitation time after extended excision, in some cases, they resort to wound restoration. With oblique excision and direct restoration, the duration of recurrence is dramatically reduced, although rehabilitation is still longer than simple drainage.²⁴ The use

of the Limberg method to treat pilonidal abscess has shown significant results in reducing the recurrence; however, a high rate of surgical complications of the wound has been revealed compared to a similar operation performed in chronic disease.²⁵ To not prolong the healing process and decrease the frequency of recurrence, they apply to open the abscess on the projection of the primary orifices, precisely on the midline, to the sacrococcygeal fascia with subsequent curettage. In this case, the frequency of relapse is dramatically reduced, although wound healing still takes a long time.²⁶ In the last decade, the endoscopic method has been used to treat acute abscesses. Wound healing is relatively fast and does not exceed six weeks, although recurrence was 21%.^{27,28}

In the guidelines of the developed countries, simple drainage of the acute abscess is recommended to be done laterally, not in the midline. After the resolution of the inflammatory process, the final operation is planned.^{11,14} However, in this case, a secondary hole is often formed in the area of the lateral incision. That is why it is necessary to expand the incision during definitive surgery. Suppose we combine the treatment duration after both interventions. In that case, we will get a rather long rehabilitation period, and the need for two surgical interventions can be considered a weakness of this approach. In our practice, we never resort to wide excision of the abscess, leaving the wound open because the healing process takes a long time, and the operation requires hospitalization of the patient, spinal or general anesthesia. We also consider it wrong to perform plastic surgery during the purulent process due to the high risk of surgical complications of the wound. Similar operations, such as Limberg plastic, should be performed after the infectious process has been resolved.

CONCLUSIONS

The pilonidal abscess drainage by minimal excision of main orifices dramatically enhances the likelihood of total healing and has a shorter rehabilitation period than simple drainage by wide excision. This straightforward procedure can be freely done in outpatient settings under local anesthesia. Patients can rapidly resume their lifestyles, and the aesthetic outcome is excellent. Drainage with minimum resection of primary ducts can be administered as a first-line, radical, outpatient treatment to patients with pilonidal abscesses.

AUTHOR AFFILIATION

1 Department of Surgery, Tbilisi State Medical University, Tbilisi, Georgia;

2 Department of Coloproctology, Todua Clinic, Tbilisi, Georgia.

REFERENCES

1. Dawson P. Pilonidal Disease. *Coloproctology*. Published online 2017;81-85. doi:https://doi.org/10.1007/978-3-662-53210-2_8.
2. Karydakis GE. Easy and Successful Treatment of Pilonidal Sinus after Explanation of Its Causative Process. *ANZ Journal of Surgery*.1992;62(5):385-389. doi:<https://doi.org/10.1111/j.1445-2197.1992.tb07208.x>.
3. Harries RL, Alqallaf A, Torkington J, Harding KG. Management of sacrococcygeal pilonidal sinus disease. *International Wound Journal*.2018;16(2):370-378. doi:<https://doi.org/10.1111/iwj.13042>.
4. Steele SR, Perry WB, Mills S, Buie WD. Practice Parameters for the Management of Pilonidal Disease. *Diseases of the Colon & Rectum*.2013;56(9):1021-1027. doi:<https://doi.org/10.1097/dcr.0b013e31829d2616>.
5. Jensen SL, Harling H. Prognosis after simple incision and drainage for a first-episode acute pilonidal abscess. *British Journal of Surgery*. 1988;75(1):60-61. doi:<https://doi.org/10.1002/bjs.1800750122>.
6. Sakr M, Ramadan M, Hamed H, Kantoush H. Secondary Healing versus Delayed Excision and Direct Closure after Incision and Drainage of Acute Pilonidal Abscess: A Controlled Randomized Trial. *Archives of Clinical and Experimental Surgery (ACES)*. 2012;1(1):8. doi:<https://doi.org/10.5455/aces.20120220101859>.
7. Vahedian J, Nabavizadeh F, Nakhuae N, Vahedian M, Sadeghpour A. Comparison between drainage and curettage in the treatment of acute pilonidal abscess. *Saudi Medical Journal*. 2005;26(4):553-555. Accessed May 16, 2023. <https://pubmed.ncbi.nlm.nih.gov/15900358/>.
8. Yildirim D, Sunamak O, Pergel A, Mounla M. Combined Single Step Definitive Treatment in Acute Pilonidal Sinus Abscess Running Head: Single Step Treatment of Pilonidal Abscess. *Surgical Science*. 2010;01(01):24-26. doi:<https://doi.org/10.4236/ss.2010.11005>.
9. de Parades V, Bouchard D, Janier M, Berger A. Pilonidal sinus disease. *Journal of Visceral Surgery*.2013;150(4):237-247. doi:<https://doi.org/10.1016/j.jviscsurg.2013.05.006>.
10. Iesalnieks I, Ommer A, Petersen S, Doll D, Herold A. German national guideline on the management of pilonidal disease. *Langenbeck's Archives of Surgery*.2016;401(5):599-609. doi:<https://doi.org/10.1007/s00423-016-1463-7>.
11. McCallum IJD, King PM, Bruce J. Healing by primary closure versus open healing after surgery for pilonidal sinus: systematic review and meta-analysis. *BMJ*. 2008;336(7649):868-871. doi:<https://doi.org/10.1136/bmj.39517.808160.be>.
12. Karim MO, Khan KA, Khan AJ, Abbas SH, Abdalla O, Aslam MI. Comparison of "Excision and Primary Repair" with "Bascom's Technique" in the Surgical Treatment of Pilonidal Sinus. *Cureus*. Published online March 20, 2020. doi:<https://doi.org/10.7759/cureus.7338>.
13. Karydakis GE. NEW APPROACH TO THE PROBLEM OF PILONIDAL SINUS. *The Lancet*.1973;302(7843):1414-1415. doi:[https://doi.org/10.1016/s0140-6736\(73\)92803-1](https://doi.org/10.1016/s0140-6736(73)92803-1).
14. Johnson EK, Vogel JD, Cowan ML, Feingold DL, Steele SR, Clinical Practice Guidelines Committee of the American Society of Colon and Rectal Surgeons. The American Society of Colon and Rectal Surgeons' Clinical Practice Guidelines for the Management of Pilonidal Disease. *Diseases of the colon and rectum*. 2019;62(2):146-157. doi:<https://doi.org/10.1097/DCR.0000000000001237>.
15. Kalaiselvan R, Bathla S, Allen W, Liyanage A, Rajaganeshan R. Minimally invasive techniques in the management of pilonidal disease. *International Journal of Colorectal Disease*. 2019;34(4):561-568. doi:<https://doi.org/10.1007/s00384-019-03260-y>.

16. Calikoglu I, Gulpinar K, Oztuna D, et al. Phenol Injection Versus Excision With Open Healing in Pilonidal Disease: A Prospective Randomized Trial. *Diseases of the Colon & Rectum*. 2017;60(2):161-169. doi:<https://doi.org/10.1097/dcr.0000000000000717>.
17. Sian TS, Herrod PJJ, Blackwell JEM, Hardy EJO, Lund JN. Fibrin glue is a quick and effective treatment for primary and recurrent pilonidal sinus disease. *Techniques in Coloproctology*. 2018;22(10):779-784. doi:<https://doi.org/10.1007/s10151-018-1864-4>.
18. Dessily M, Charara F, Ralea S, Allé JL. Pilonidal sinus destruction with a radial laser probe: technique and first Belgian experience. *Acta Chirurgica Belgica*. 2017;117(3):164-168. doi:<https://doi.org/10.1080/00015458.2016.1272285>.
19. Pronk AA, Eppink L, Smakman N, Furnee EJB. The effect of hair removal after surgery for sacrococcygeal pilonidal sinus disease: a systematic review of the literature. *Techniques in Coloproctology*. 2017;22(1):7-14. doi:<https://doi.org/10.1007/s10151-017-1722-9>.
20. Milone M, Musella M, Di Spiezio Sardo A, et al. Video-assisted ablation of pilonidal sinus: A new minimally invasive treatment—A pilot study. *Surgery*. 2014;155(3):562-566. doi:<https://doi.org/10.1016/j.surg.2013.08.021>.
21. Meinerio P, Stazi A, Carbone A, Fasolini F, Regusci L, La Torre M. Endoscopic pilonidal sinus treatment: a prospective multicentre trial. *Colorectal Disease*. 2016;18(5):O164-O170. doi:<https://doi.org/10.1111/codi.13322>.
22. Webb PM, Wysocki AP. Does pilonidal abscess heal quicker with off-midline incision and drainage? *Techniques in Coloproctology*. 2011;15(2):179-183. doi:<https://doi.org/10.1007/s10151-011-0684-6>.
23. Licheri S, Pisano G, Erdas E, Farci S, Pomata M, Daniele GM. Radical treatment of acute pilonidal abscess by marsupialization. *Il Giornale Di Chirurgia*. 2004;25(11-12):414-416. Accessed May 19, 2023. <https://pubmed.ncbi.nlm.nih.gov/15803819/>.
24. Ciftci F, Abdurrahman I, Tosun M, Bas G. A new approach: oblique excision and primary closure in the management of acute pilonidal disease. *International journal of clinical and experimental medicine*. 2014;7(12):5706-5710. Accessed May 19, 2023. <https://www.ncbi.nlm.nih.gov/pmc/articles/PMC4307542/#b37>.
25. Driouch J, Braumann C, Dehnst J, et al. [Results of the Limberg flap procedure in acute and chronic pilonidal abscesses]. *Der Chirurg; Zeitschrift Fur Alle Gebiete Der Operativen Medizin*. 2022;93(2):182-189. doi:<https://doi.org/10.1007/s00104-021-01439-0>.
26. Kepenekci I, Demirkan A, Celasin H, Gecim IE. Unroofing and curettage for the treatment of acute and chronic pilonidal disease. *World Journal of Surgery*. 2010;34(1):153-157. doi:<https://doi.org/10.1007/s00268-009-0245-6>.
27. Javed MA, Fowler H, Jain Y, Singh S, Scott M, Rajaganeshan R. Comparison of conventional incision and drainage for pilonidal abscess versus novel endoscopic pilonidal abscess treatment (EPAT). *Techniques in Coloproctology*. 2016;20(12):871-873. doi:<https://doi.org/10.1007/s10151-016-1546-z>.
28. Jain Y, Javed M, Singh S, Rout S, Joshi H, Rajaganeshan R. Endoscopic pilonidal abscess treatment: a novel approach for the treatment of pilonidal abscess. *The Annals of The Royal College of Surgeons of England*. 2017;99(2):134-136. doi:<https://doi.org/10.1308/rcsann.2016.0260>.